

# 2 Microscopic Anatomy of the Periodontium

<b>Section 1</b>	<b>Histology of the Body's Tissues</b>	<b>24</b>
	Microscopic Anatomy of a Tissue Microscopic Anatomy of Epithelial Tissue Microscopic Anatomy of Connective Tissue Epithelial–Connective Tissue Interface Epithelial Cell Junctions	
<b>Section 2</b>	<b>Histology of the Gingiva</b>	<b>29</b>
	Microscopic Anatomy of Gingival Epithelium Why the Teeth Need a Junctional Epithelium Attachment of the Cells of the Junctional Epithelium Microscopic Anatomy of Gingival Connective Tissue	
<b>Section 3</b>	<b>Histology of Root Cementum and Alveolar Bone</b>	<b>41</b>
	Microscopic Anatomy of Cementum Microscopic Anatomy of Alveolar Bone	
<b>Section 4</b>	<b>Focus on Patients</b>	<b>46</b>
	Clinical Patient Care Evidence in Action: Clinical Relevance	

**Clinical Application.** Dental health care providers continuously interact with patients when making clinical decisions, performing clinical procedures, evaluating new techniques, and adapting to emerging treatment approaches. Nearly every action taken by a clinician requires a detailed knowledge of the anatomy of the tooth-supporting structures—the periodontium. Chapter 1 dealt with what is known about the fundamental structure of the complex system of tissues that support the teeth. Chapter 2 deals with the microscopic anatomy of these same structures. The information presented in these two chapters can serve as a basis for organizing thoughts about additional anatomical information as it becomes available through additional research.

## Learning Objectives

- Describe the histology of the tissues and the function that each serves in the human body.
- List and define the layers that comprise the stratified squamous epithelium of the skin.
- Define keratin and describe its function in the epithelium.
- Describe the composition and function of connective tissue.
- Describe the epithelial–connective tissue interface found in most tissues of the body, such as the interface between the epithelium and connective tissues of the skin.
- Define the term *cell junction* and describe its function in the epithelial tissues.
- Compare and contrast the terms *desmosome* and *hemidesmosome*.
- Identify the three anatomical areas of the gingival epithelium on an unlabeled drawing depicting the microscopic anatomy of the gingival epithelium.
- Describe the location and function of the following regions of the gingival epithelium: oral epithelium, sulcular epithelium, and junctional epithelium.
- State the level of keratinization present in each of the three anatomical areas of the gingival epithelium (keratinized, nonkeratinized, or parakeratinized).
- State which of the anatomical areas of the gingival epithelium have an uneven, wavy epithelial–connective tissue interface **in health** and which have a smooth junction **in health**.
- Identify the enamel, gingival connective tissue, junctional epithelium, internal basal lamina, external basal lamina, epithelial cells, desmosomes, and hemidesmosomes on an unlabeled drawing depicting the microscopic anatomy of the junctional epithelium and surrounding tissues.
- Define and describe the function of the supragingival fiber bundles and the periodontal ligament in the periodontium.
- Identify the fiber groups of the periodontal ligament on an unlabeled drawing.
- Define the terms *cementum* and *Sharpey fibers* and describe their function in the periodontium.
- State the three relationships that the cementum may have in relation to the enamel at the cemento–enamel junction.
- Define the term *alveolar bone* and describe its function in the periodontium.

## Key Terms

Histology	Keratinized epithelial cells	Cell junctions	Keratin	Periodontal ligament (PDL)
Tissue	Nonkeratinized epithelial cells	Desmosome	Gingival crevicular fluid	Fiber bundles of the PDL
Cells	Connective tissue	Hemidesmosome	Internal basal lamina	Sharpey fibers
Extracellular matrix	Epithelial–connective tissue interface	Gingival epithelium	External basal lamina	Cementum
Epithelial tissue	Basement membrane	Oral epithelium (OE)	Collagen fibers	Cementum proteins
Stratified squamous epithelium	Epithelial ridges	Sulcular epithelium (SE)	Supragingival fiber bundles	OMG (overlap, meet, gap)
Basal lamina	Connective tissue papillae	Junctional epithelium (JE)	Dentogingival unit	Alveolar process
Keratinization		Keratinized	Periosteum	Bone remodeling
		Parakeratinized		

## Section 1

# Histology of the Body's Tissues

**Histology** is a branch of anatomy concerned with the study of the microscopic features of tissues. Knowledge of the microscopic characteristics of tissues is a prerequisite for understanding the microscopic anatomy of the periodontium. Section 1 reviews the microscopic anatomy of the epithelial and connective tissues of the body.

## MICROSCOPIC ANATOMY OF A TISSUE

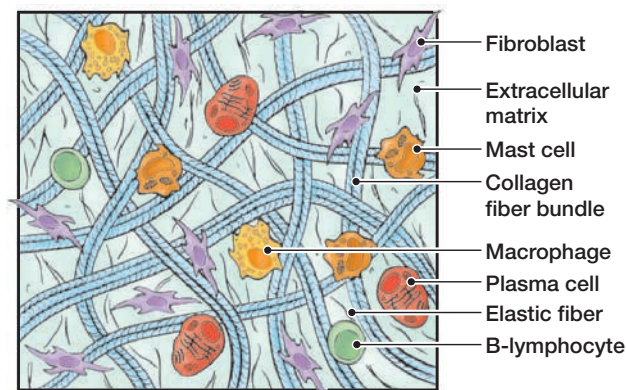
A **tissue** is a group of interconnected cells that perform a similar function within an organism. For example, muscle cells group together to form muscle tissue that functions to move parts of the body. The tissues and organs of the body are composed of several different types of cells and extracellular elements outside of the cells.

### 1. Cells

- A. **Cells** are the smallest structural unit of living matter capable of functioning independently.
- B. Cells group together to form a tissue.
- C. The four basic types of tissue are epithelial, connective, nerve, and muscle tissues.

### 2. Extracellular Matrix. Tissues are not made up solely of cells. A gel-like substance containing interwoven protein fibers surrounds most cells.

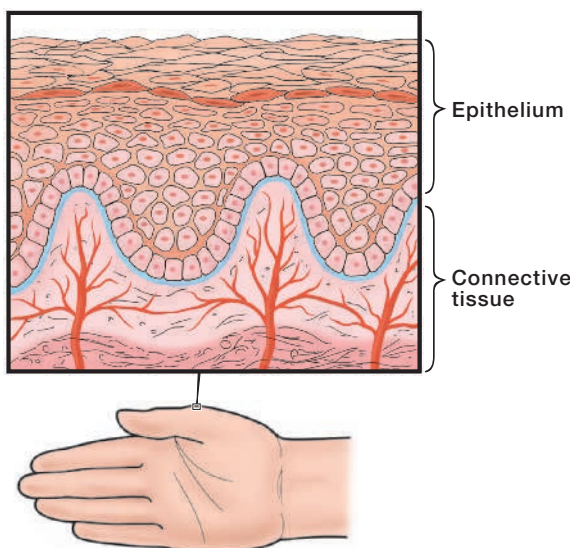
- A. The **extracellular matrix** is a mesh-like material that surrounds the cells (Fig. 2-1). It is like a structural and biomechanical scaffold for the cells. This material helps to hold cells together and provides a framework within which cells can migrate and interact with one another.
- B. The extracellular matrix consists of ground substance and fibers.
  - 1. The ground substance is a gel-like material that fills the space between the cells.
  - 2. The fibers consist of collagen, elastin, and reticular fibers. Collagens are the major proteins of the extracellular matrix.
- C. Amount of Extracellular Matrix
  - 1. In epithelial tissue, the extracellular matrix is sparse, consisting mainly of a thin mat called the basal lamina, which underlies the epithelium.
  - 2. In connective tissue, the extracellular matrix is more plentiful than the cells that it surrounds.



**Figure 2-1. Extracellular Matrix.** The extracellular matrix surrounds the cells of a tissue and is comprised of fibers and a gel-like substance.

## MICROSCOPIC ANATOMY OF EPITHELIAL TISSUE

1. **Description.** The **epithelial tissue** is the tissue that makes up the outer surface of the body (skin or epidermis) and lines the body cavities such as the mouth, stomach, and intestines (mucosa). The skin and mucosa of the oral cavity are made up of **stratified squamous epithelium**—a type of epithelium that is comprised of flat cells arranged in several layers.
2. **Composition of Epithelial Tissue**
  - A. **Plentiful Cells.** Most of the volume of epithelial tissue consists of many closely packed epithelial cells (Fig. 2-2). Epithelial cells are bound together into sheets.
  - B. **Sparse Extracellular Matrix**
    1. The extracellular matrix is a minor component of the epithelial tissue existing mainly in the basal lamina.
    2. The **basal lamina** is a thin mat of extracellular matrix secreted by the epithelial cells. This basal lamina mat supports the epithelium (somewhat like the scaffolding of a building).
3. **Keratinization. Keratinization**—the process by which epithelial cells on the surface of the skin become stronger and waterproof.
  - A. **Keratinized Epithelial Cells**
    1. **Keratinized epithelial cells** have no nuclei and form a tough, resistant layer on the surface of the skin.
    2. The most heavily keratinized epithelium of the body is found on the palms of the hands and soles of the feet.
  - B. **Nonkeratinized Epithelial Cells**
    1. **Nonkeratinized epithelial cells** have nuclei and act as a cushion against mechanical stress and wear. Nonkeratinized epithelial cells are softer and more flexible.
    2. Nonkeratinized epithelium is found in areas such as the mucosal lining of the cheeks—permitting the mobility needed to speak, chew, and make facial expressions.
4. **Blood Supply.** Epithelial tissues are avascular—containing no blood vessels. The epithelial layer receives oxygen and nourishment from blood vessels located in the underlying connective tissue via a process known as diffusion (Fig. 2-2).



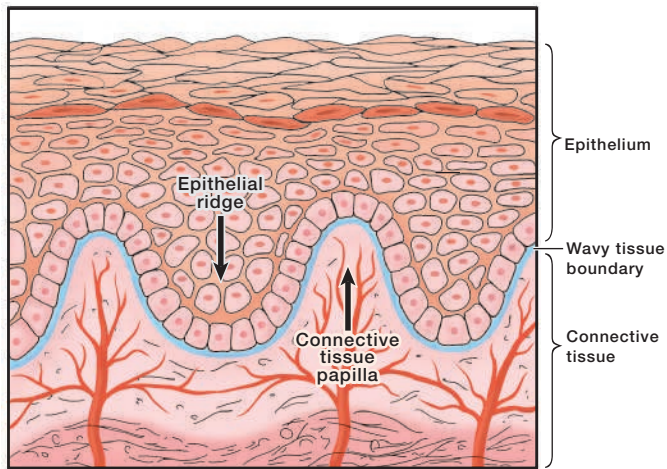
**Figure 2-2. Stratified Squamous Epithelium and Connective Tissue of the Skin.** The epithelium of the skin consists of many closely packed epithelial cells and a thin basal lamina. The epithelium of the skin rests on a supporting bed of connective tissue. The epithelium does not contain blood vessels; nourishment is received from blood vessels in the underlying connective tissue.

## MICROSCOPIC ANATOMY OF CONNECTIVE TISSUE

1. **Description.** **Connective tissue** fills the spaces between the tissues and organs in the body. It supports and binds other tissues. Connective tissue consists of cells separated by abundant extracellular substance.
2. **Composition of Connective Tissue**
  - A. **Sparse Cells.** Connective tissue cells are sparsely distributed in the extracellular matrix.
    1. Fibroblasts (“fiber-builders”)—cells that form the extracellular matrix (fibers and ground substance) and secrete it into the intercellular spaces
    2. Macrophages and neutrophils—phagocytes (“cell-eaters”) that devour dying cells and microorganisms that invade the body
    3. Lymphocytes—cells that play a major role in the immune response
  - B. **Plentiful Extracellular Matrix.** The extracellular matrix—a rich gel-like substance containing a network of strong fibers—is the major component of connective tissue. The network of the fiber matrix, rather than the cells, gives connective tissue the strength to withstand mechanical forces.
3. **Dental Connective Tissue.** All dental tissues of the tooth—cementum, dentin, alveolar bone, and the pulp—are specialized forms of connective tissue *except enamel*. Enamel is an epithelial tissue.

## EPITHELIAL–CONNECTIVE TISSUE INTERFACE

1. **Description.** The **epithelial–connective tissue interface** is the boundary where the epithelial and connective tissues meet.
2. **The Basement Membrane and Basal Lamina**
  - A. As discussed previously, the basal lamina is a thin layer secreted by the epithelial cells on which the epithelium sits. The term *basal lamina* often is confused with the term *basement membrane* and is sometimes used inconsistently in the literature.
  - B. The basal lamina is not visible under the light microscope, but can be distinguished under the higher magnification of an electron microscope. The basal lamina assists the attachment of the epithelial cells to adjacent structures, such as the tooth surface.
  - C. The term **basement membrane** specifies a thin layer of tissue visible with a light microscope beneath the epithelium. The basement membrane is formed by the combination of a basal lamina and a reticular lamina.
3. **Characteristics of the Epithelial–Connective Tissue Boundary**
  - A. **Wavy Boundary.** In most places in the body, the epithelium meets the connective tissue in a wavy, uneven manner (Fig. 2-3).
    1. **Epithelial ridges**—deep extensions of epithelium that reach down into the connective tissue. The epithelial ridges are also known as rete pegs.
    2. **Connective tissue papillae**—finger-like extensions of connective tissue that project up and interlock with the epithelium.
  - B. **Smooth Boundary**
    1. Some specialized epithelial tissues in the body meet the connective tissue in a smooth interface that has no epithelial ridges or connective tissue papillae.
    2. Some anatomical areas of the gingiva have an epithelial–connective tissue interface that is smooth.



**Figure 2-3. Wavy Epithelial-Connective Tissue Interface.** In most cases, the epithelium meets the connective tissue at an uneven, wavy border. Epithelial ridges extend down into the connective tissue. Connective tissue papillae extend upward into the epithelium.

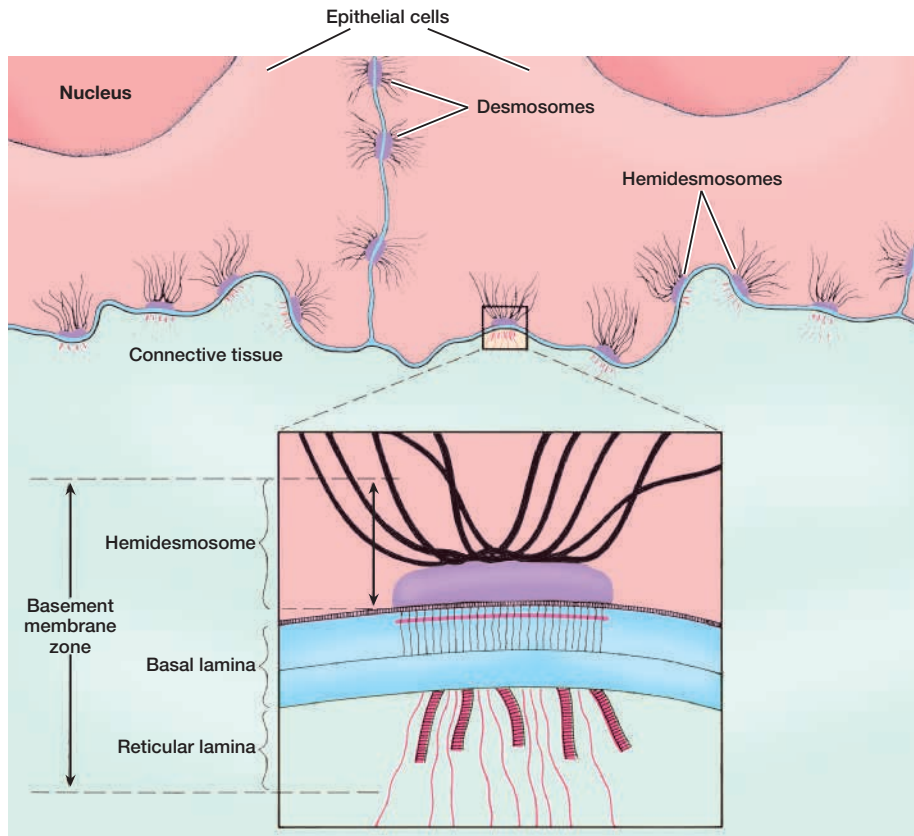
#### 4. Function of the Wavy Tissue Boundary

- A. Enhances Adhesion.** The wavy tissue interface enhances the adhesion of the epithelium to the connective tissue by increasing the surface area of the junction between the two tissues. This strong adhesion of the epithelium allows the skin to resist mechanical forces.
- B. Provides Nourishment.** The wavy junction between the epithelium and connective tissue also increases the area from which the epithelium can receive nourishment from the underlying connective tissue. The epithelium does not have its own blood supply; blood vessels are carried close to the epithelium in the connective tissue papillae.

## EPITHELIAL CELL JUNCTIONS

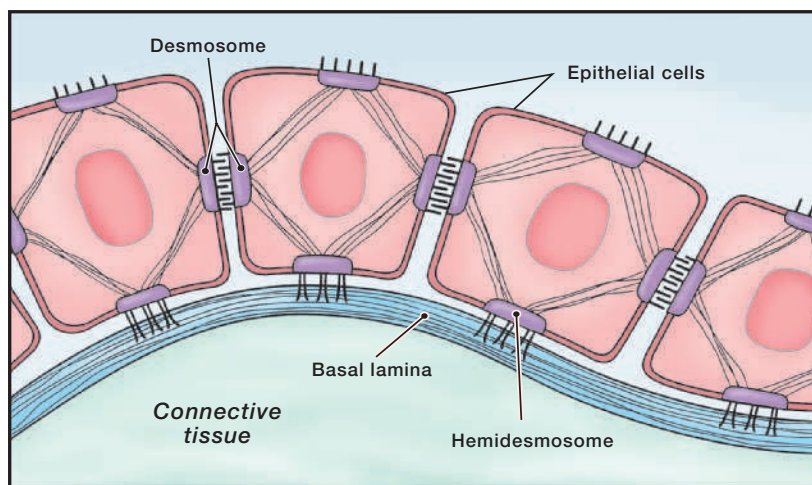
Neighboring epithelial cells attach to one another by specialized cell junctions that give the tissue strength to withstand mechanical forces and to form a protective barrier.

- 1. Definition.** **Cell junctions** are cellular structures that mechanically attach a cell and its cytoskeleton to its neighboring cells or to the basal lamina.
- 2. Purpose.** Cell junctions bind cells together so that they can function as a strong structural unit. Tissues, such as the epithelium of the skin that must withstand severe mechanical stresses, have the most abundant number of cell junctions.
- 3. Types of Epithelial Cell Junctions**
  - A. Desmosome**—a specialized cell junction that connects two neighboring epithelial cells and their cytoskeletons together. You might think of desmosomes as being like the snaps used to close a denim jacket. Instead of fastening the front of a jacket together, desmosomes fasten epithelial cells together (Fig. 2-4A,B).
    1. A cell-to-cell connection
    2. An important form of cell junction found in the gingival epithelium
  - B. Hemidesmosome**—a specialized cell junction that connects the epithelial cells to the basal lamina (Fig. 2-4A,B). You might think of hemidesmosomes as specialized structures that represent half of a desmosome.
    1. A cell-to-basal lamina connection
    2. An important form of cell junction found in the gingival epithelium



A

**Figure 2-4A. The Epithelial–Connective Tissue Interface.** The epithelial–connective tissue interface is the site of the basement membrane zone, a complex structure mostly synthesized by the epithelial cells. **Inset:** A representation of an electron micrograph showing the hemidesmosomal attachment to the basal lamina. (Adapted with permission from Rubin R, Strayer DS. *Rubin’s Pathology: Clinicopathologic Foundations of Medicine*. 5th ed. Philadelphia, PA: Lippincott Williams & Wilkins; 2008.)



B

**Figure 2-4B. Epithelial Cell Junctions.** Epithelial cells attach to each other with specialized cell junctions called desmosomes. Hemidesmosomes attach the epithelial cells to the basal lamina.

## Section 2

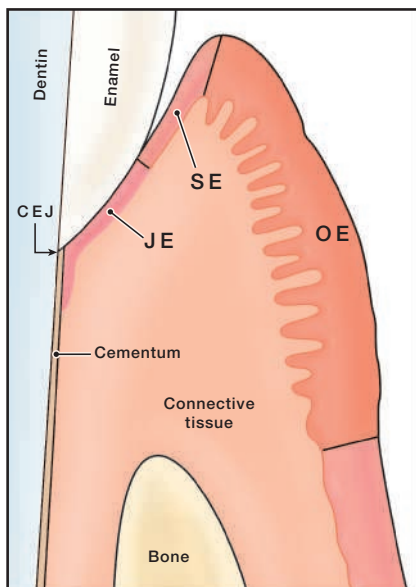
# Histology of the Gingiva

Knowledge of the microscopic anatomy of the gingiva is a prerequisite for understanding the periodontium in health and in disease. At first glance, the microscopic anatomy of the periodontium may seem to be complicated.<sup>1</sup> The anatomy of the periodontium, however, is much like that of tissues elsewhere in the body. **The gingiva consists of an epithelial layer and an underlying connective tissue layer.** This section reviews the microscopic anatomy of the gingival epithelium, junctional epithelium, and gingival connective tissues.

### MICROSCOPIC ANATOMY OF GINGIVAL EPITHELIUM

The **gingival epithelium** is a specialized stratified squamous epithelium that functions well in the wet environment of the oral cavity.<sup>2</sup> The microscopic anatomy of the gingival epithelium is like that of the epithelium of the skin. The gingival epithelium may be differentiated into three anatomical areas (Fig. 2-5):

1. **Oral Epithelium (OE):** epithelium that faces the oral cavity
2. **Sulcular Epithelium (SE):** epithelium that faces the tooth surface *without being in contact with the tooth surface*
3. **Junctional Epithelium (JE):** epithelium that attaches the gingiva to the tooth



**Figure 2-5. Three Areas of the Gingival Epithelium.** The gingival epithelium has three distinct areas:

- **JE**—junctional epithelium at the base of the sulcus
- **SE**—sulcular epithelium that lines the sulcus
- **OE**—oral epithelium covering the free and attached gingiva

1. **Oral Epithelium (OE).** The **oral epithelium** covers the outer surface of the free gingiva and attached gingiva; it extends from the crest of the gingival margin to the mucogingival junction. The oral epithelium is the only part of the periodontium that is visible to the unaided eye.

#### A. Cellular Structure of the Oral Epithelium (OE)

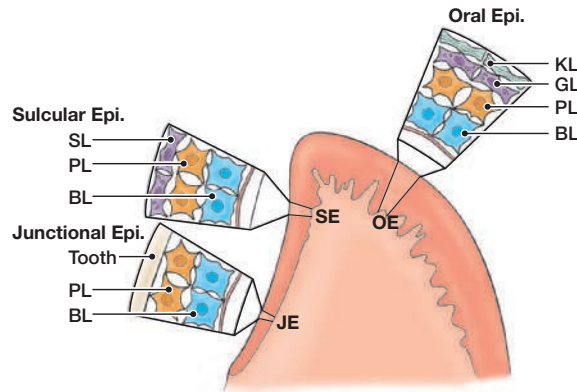
1. The oral epithelium may be **keratinized** or **parakeratinized** (partially keratinized). **Keratin** is a tough, fibrous structural protein that occurs in the outer layer of the skin and the oral epithelium (Fig. 2-6).

2. The oral epithelium is stratified squamous epithelium that can be divided into cell layers (Fig. 2-6). The layers are listed below in order from the deepest layer to the most superficial layer.
  - a. Basal cell layer (stratum basale): cube-shaped cells
  - b. Prickle cell layer (stratum spinosum): spine-like cells with large intercellular spaces. The cells of both the basal and prickle cell layers attach to each other with desmosomes.
  - c. Granular cell layer (stratum granulosum): flattened cells and increased intracellular keratin
  - d. Keratinized cell layer (stratum corneum): flattened cells with extensive intracellular keratin.

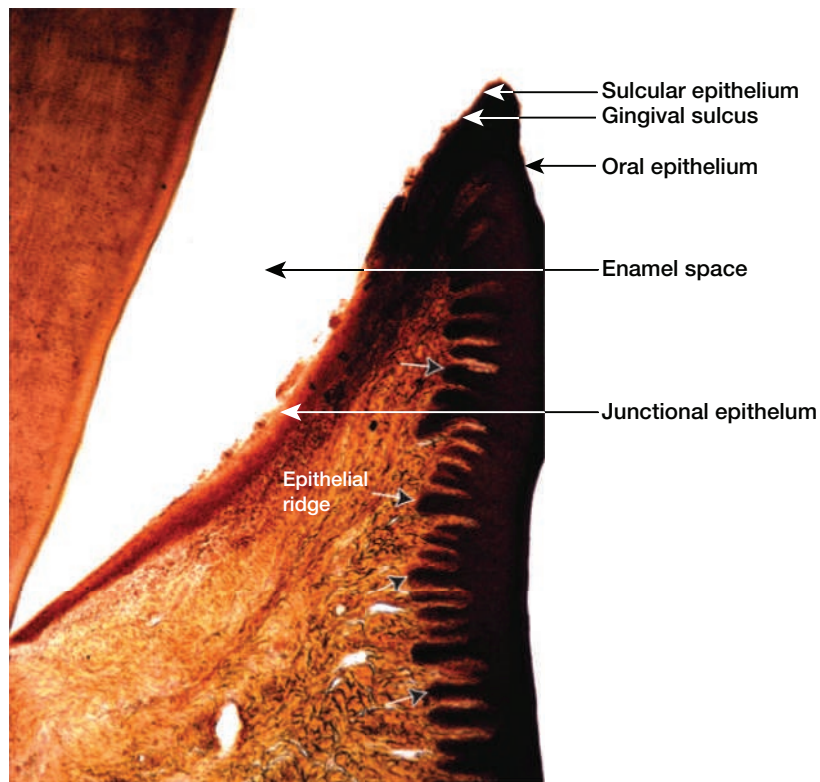
**B. Interface with Gingival Connective Tissue.** *In health, oral epithelium joins with the connective tissue in a wavy interface with epithelial ridges (Figs. 2-7 and 2-8).*
2. **Sulcular Epithelium.** **Sulcular epithelium (SE)** is the epithelial lining of the gingival sulcus. It is continuous with the oral epithelium and extends from the crest of the gingival margin to the coronal edge of the junctional epithelium.
  - A. Cellular Structure of the Sulcular Epithelium (SE)**
    1. The sulcular epithelium is a thin, nonkeratinized epithelium.<sup>3</sup>
    2. The sulcular epithelium has three cellular layers (Fig. 2-6):
      - a. Basal cell layer
      - b. Prickle cell layer
      - c. Superficial cell layer: flattened cells without keratin
    3. The sulcular epithelium is permeable allowing fluid to flow from the gingival connective tissue into the sulcus. This fluid is known as the **gingival crevicular fluid**. The flow of gingival crevicular fluid is slight in health and increases in disease.

**B. Interface with Gingival Connective Tissue.** In health, the sulcular epithelium joins the connective tissue at a *smooth interface* with no epithelial ridges (no wavy junction).
  3. **Junctional Epithelium.** **Junctional epithelium (JE)** is the specialized epithelium that forms the base of the sulcus and joins the gingiva to the tooth surface. *The gingiva surrounds the cervix of the tooth and attaches to the tooth by means of the junctional epithelium. The base of the sulcus is made up of the coronal-most cells of the junctional epithelium.* In health, the JE attaches to the tooth at a level that is slightly coronal to the cemento-enamel junction (CEJ).
    - A. Cellular Structure of the Junctional Epithelium (JE)**
      1. Keratinization of JE
        - a. The junctional epithelium is a thin, nonkeratinized epithelium.
        - b. Nonkeratinized epithelial cells of both the sulcular and junctional areas of the gingival epithelium make them a less effective protective covering. Thus, the sulcular and junctional areas provide the easiest point of entry for bacteria or bacterial products to invade the connective tissue of the gingiva.
      2. The junctional epithelium has only two cell layers (Figs. 2-6 and 2-7):
        - a. Basal cell layer
        - b. Prickle cell layer
      3. Length and Width of JE
        - a. The junctional epithelium ranges from 0.71 to 1.35 mm in length.<sup>4</sup>
        - b. The JE is about 15 to 30 cells thick at the coronal zone—the zone that attaches highest on the crown of the tooth.
        - c. The JE tapers from 4 to 5 cells thick at the apical zone.

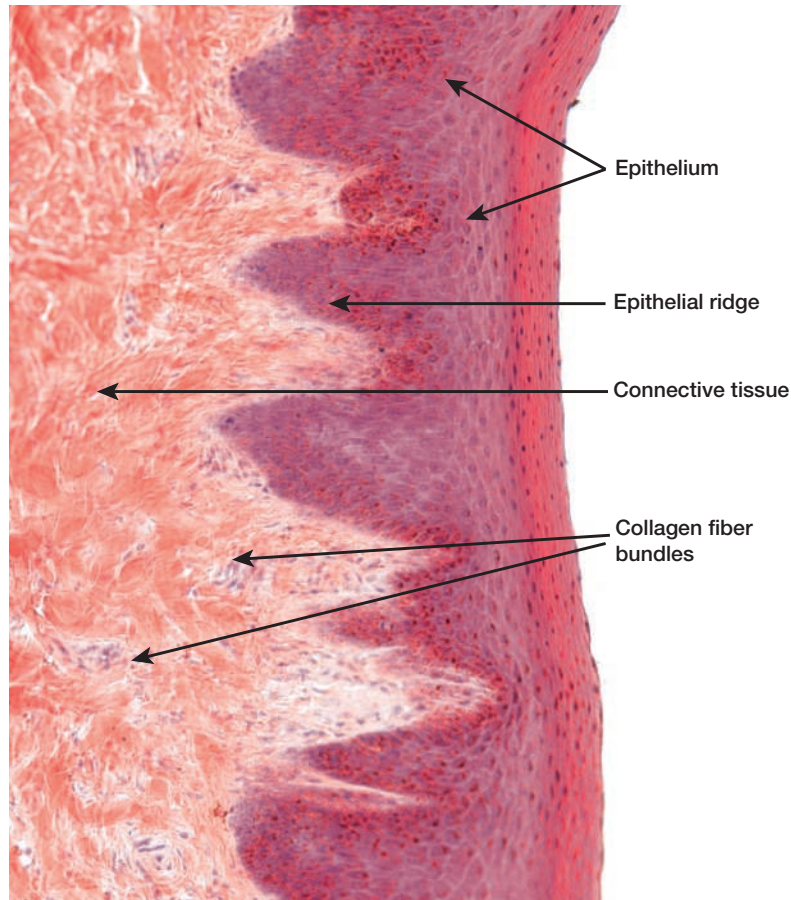
**B. JE Interface with Gingival Connective Tissue.** In health, the junctional epithelium has a *smooth tissue interface* with the connective tissue (no wavy junctions).



**Figure 2-6. Cell Layers of the Gingival Epithelium.** The cell layers of the oral, sulcular, and junctional epithelium. Illustration key: KL, keratinized cell layer; GL, granular cell layer; SL, superficial cell layer; PL, prickle cell layer; BL, basal cell layer.



**Figure 2-7. Human Gingiva.** This photograph shows a decalcified longitudinal section of an incisor tooth as seen through an ordinary light microscope. All the calcium hydroxyapatite crystals have been extracted from the tooth and from its bony alveolus. Since enamel is composed almost completely of calcium hydroxyapatite crystals, only the space where enamel used to be—the enamel space—is represented in this photograph. The sulcular epithelium of the free gingiva borders a space known as the gingival sulcus. Observe the well-developed epithelial ridges (identified by label and arrows) of the oral epithelium. (Adapted with permission from Gartner LP, Hiatt JL. *Color Atlas and Text of Histology*. Philadelphia, PA: Lippincott Williams & Wilkins; 2013.)



**Figure 2-8. Epithelial Ridges.** This photograph shows the epithelial–connective junction as seen through an ordinary light microscope. The tall epithelial ridges of the epithelium (*in dark red*) project into the underlying connective tissue. Collagen fiber bundles are visible in the connective tissue. (Adapted with permission from Gartner LP, Hiatt JL. *Color Atlas and Text of Histology*. Philadelphia, PA: Lippincott Williams & Wilkins; 2013.)

## WHY THE TEETH NEED A JUNCTIONAL EPITHELIUM

### 1. The Teeth Create a Break in the Epithelial Protective Covering

#### A. Protective Epithelial Sheet Covers the Body

1. A continuous sheet of epithelium protects the body by covering its outer surfaces and lining the body's cavities, including the oral cavity.
2. The teeth penetrate this protective covering by erupting through the epithelium, thus creating an opening through which microorganisms can enter the body.

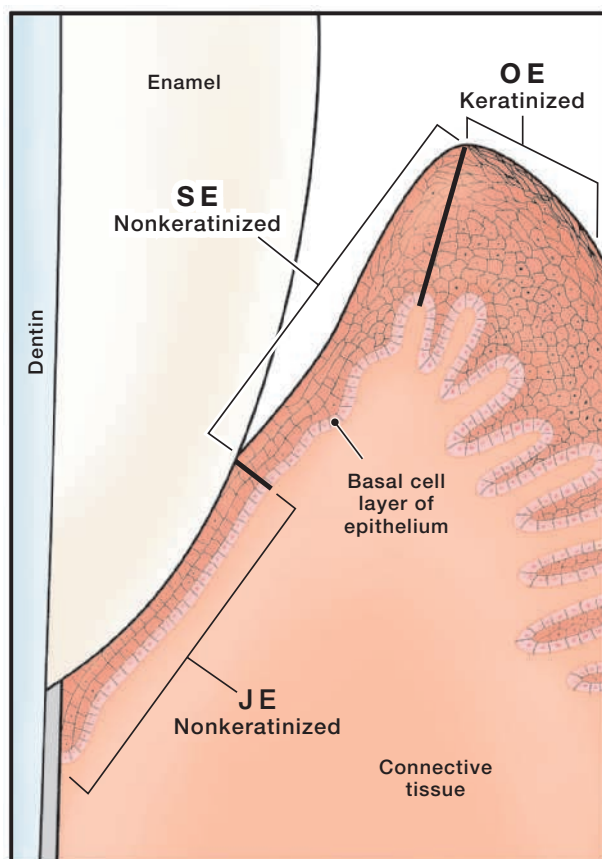
#### B. The Teeth Puncture the Protective Epithelial Sheet

1. The body attempts to seal the opening created when a tooth penetrates the epithelium by attaching the epithelium to the tooth.
2. The word “junction” means “connection”; thus, the epithelium that is connected to the tooth is termed the “junctional epithelium.”

### 2. Functions of the Junctional Epithelium

- #### A. Epithelial Attachment.
- The junctional epithelium provides an attachment between the gingiva and the tooth surface, thus providing a seal at the base of the gingival sulcus or periodontal pocket (Fig. 2-9).

- B. Barrier.** The junctional epithelium provides a protective barrier between the plaque biofilm and the connective tissue of the periodontium.
- C. Host Defense.** The epithelial cells play a role in defending the periodontium from bacterial infection by signaling the immune response.<sup>5</sup>



**Figure 2-9. Microscopic Anatomy of the Three Areas of the Gingival Epithelium. Interface with Connective Tissue.**

- **OE** (oral epithelium)—these epithelial cells form the outer layer of the free and attached gingiva.
- **SE** (sulcular epithelium)—these epithelial cells extend from the edge of the junctional epithelium coronally to the crest of the gingival margin.
- **JE** (junctional epithelium)—these epithelial cells join the gingiva to the tooth surface at the base of the sulcus.

## ATTACHMENT OF THE CELLS OF THE JUNCTIONAL EPITHELIUM

### 1. Microscopic Anatomy of Junctional Epithelium

**A. Components of the Junctional Epithelium (JE).** The junctional epithelium consists of:

1. Plentiful Cells
  - a. Layers of closely packed epithelial cells
  - b. Desmosomes and hemidesmosomes—specialized cell junctions
2. A Sparse Extracellular Matrix
  - a. **Internal basal lamina**—a thin basal lamina between the junctional epithelium and the tooth surface.
  - b. **External basal lamina**—a thin basal lamina between the junctional epithelium and the gingival connective tissue.

### 2. Attachment of Junctional Epithelium to the Tooth Surface

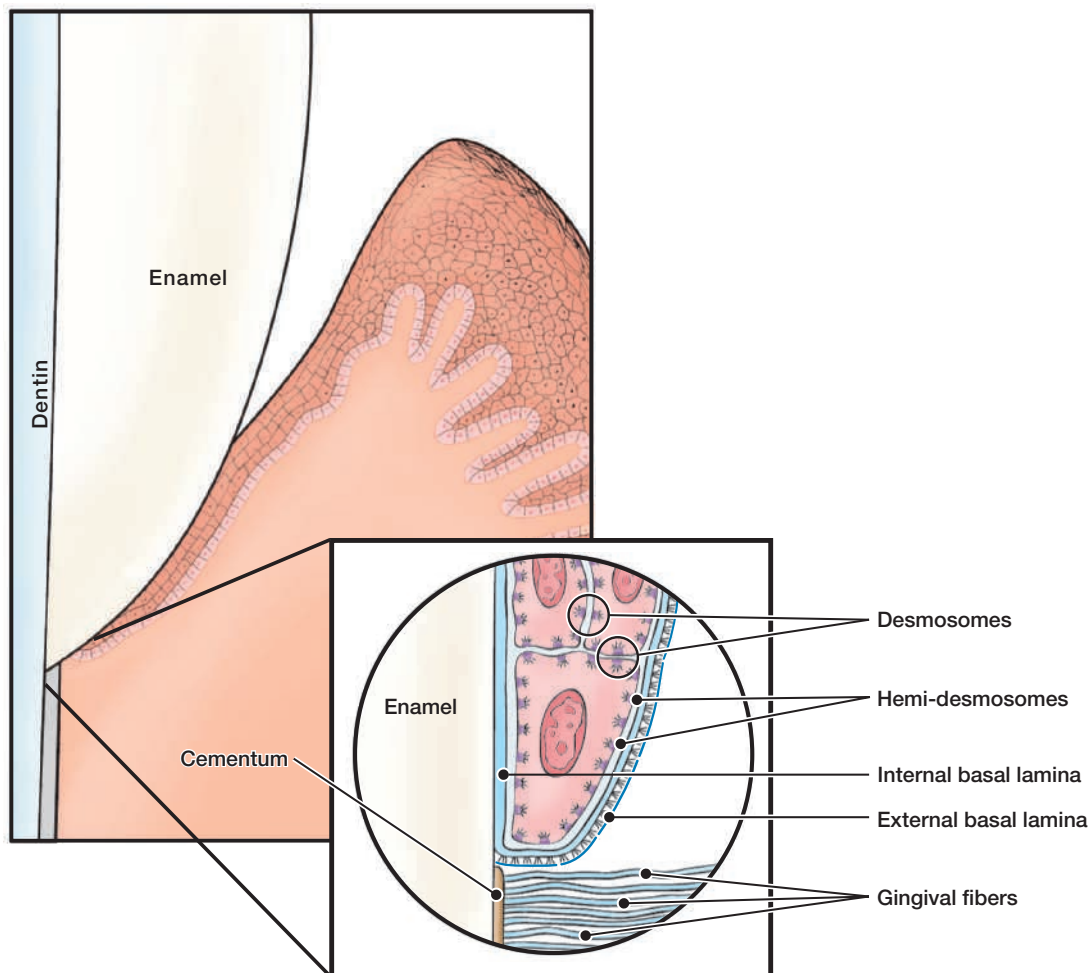
**A. Attachment to the Tooth Surface**

1. The JE cells next to the tooth surface form *hemidesmosomes* that enable these cells to attach to the *internal basal lamina* and the surface of the tooth.<sup>6-9</sup>

2. The internal basal lamina is a thin sheet of extracellular matrix adjacent to the tooth surface.
3. The epithelial cells physically attach to the tooth surface by four to eight hemidesmosomes per micron at the coronal zone and two hemidesmosomes per micron in the apical zone of the junctional epithelium.<sup>10,11</sup> The apical zone is the area of the junctional epithelium with the least adhesiveness.
4. The attachment of the hemidesmosomes and internal basal lamina to the tooth surface is not static; rather, the cells of the junctional epithelium can move along the tooth surface.

**B. Attachment to the Underlying Gingival Connective Tissue**

1. The epithelial cells of the JE attach to the underlying *gingival connective tissue* via *hemidesmosomes* and the *external basal lamina* (Fig. 2-10).<sup>8,12,13</sup>
2. In health, the junctional epithelium has a *smooth tissue interface* with the connective tissue (no wavy junctions).



**Figure 2-10. Microscopic Anatomy of the Junctional Epithelium (JE).** Microscopic structures of the junctional epithelium include the epithelial cells, desmosomes, external and internal basal laminae, and hemidesmosomes.

## MICROSCOPIC ANATOMY OF GINGIVAL CONNECTIVE TISSUE

1. **Function of Gingival Connective Tissue.** The gingival connective tissue of the free and attached gingiva provides solidity to the gingiva and attaches the gingiva to the cementum of the root and the alveolar bone.<sup>14-16</sup> The gingival connective tissue is also known as the lamina propria.

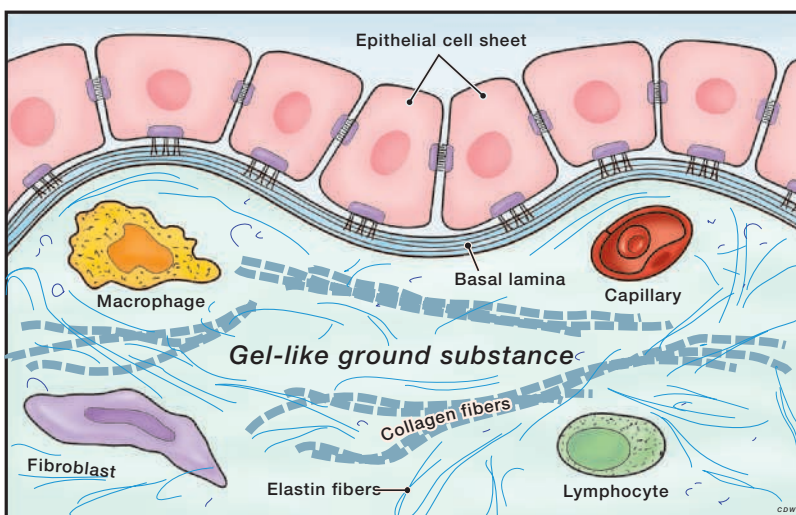
### 2. Components of the Gingival Connective Tissue

#### A. Cells

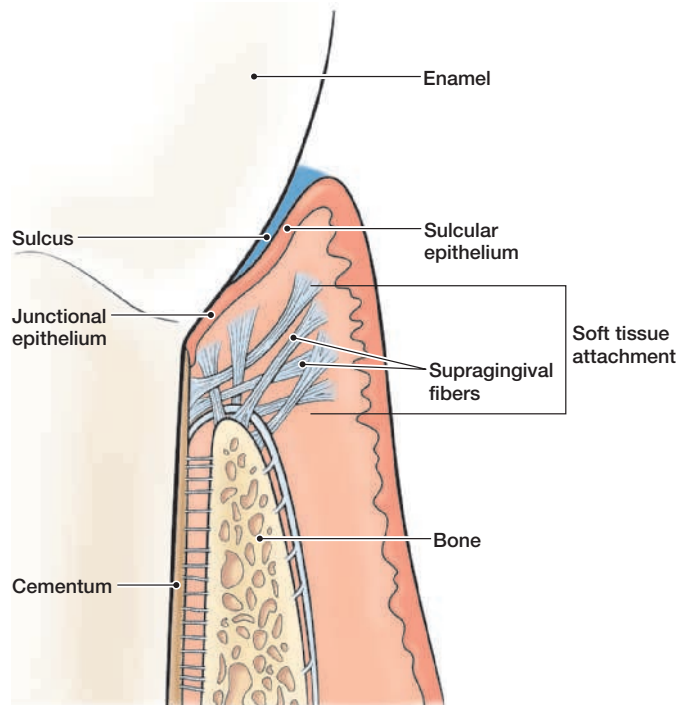
1. In contrast to the gingival epithelium (which has an abundance of cells and sparse extracellular matrix), the gingival connective tissue has an abundance of extracellular matrix and few cells (Fig. 2-11).
2. Cells comprise about 5% of the gingival connective tissue.
3. The different types of cells present in the gingival connective tissue are:
  - a. Fibroblasts
  - b. Mast cells
  - c. Immune cells, such as macrophages, neutrophils, and lymphocytes.
4. The fibers of the connective tissue are produced by the fibroblasts.

#### B. Extracellular Matrix

1. The major components of the connective tissue are collagen fibers, fibroblasts, vessels, and nerves that are embedded in the extracellular matrix. The matrix of the connective tissue is produced mainly by the fibroblasts.
2. The matrix is the medium in which the connective tissue cells are embedded and it is essential for the maintenance of the normal function of the connective tissue. The transportation of water, nutrients, metabolites, oxygen, etc., to and from the individual connective tissue cells occurs within the matrix.
3. Protein fibers account for about 55% to 65% of the gingival connective tissue. Most of these are **collagen fibers** that form a dense network of strong, rope-like cables that secure and hold the gingival connective tissues together.
4. The collagen fibers enable the gingiva to form a rigid cuff around the tooth.
5. Gel-like material between the cells makes up about 30% to 35% of the gingival connective tissue. This gel-like material helps to hold the tissue together.



**Figure 2-11. Microscopic Anatomy of Gingival Connective Tissue.** The gingival connective tissue is comprised of a gel-like substance, protein fibers, and cells.



**Figure 2-12. Supragingival Fibers of Gingival Connective Tissue.** The gingival fibers are rope-like collagen fiber bundles in the gingival connective tissue. These fibers form a soft tissue attachment coronal to the alveolar bone.

3. **The Supragingival Fiber Bundles of the Gingival Connective Tissue.** The **supragingival fiber bundles (gingival fibers)** are a network of rope-like collagen fiber bundles in the gingival connective tissue (Fig. 2-12). These fibers are located coronal to (above) the crest of the alveolar bone.

**A. Characteristics of the Fiber Bundles**

1. The fiber bundles are embedded in the gel-like extracellular matrix of the gingival connective tissue.
2. The subgingival fiber bundles strengthen the attachment of the junctional epithelium to the tooth by bracing the gingival margin against the tooth surface.
3. Together the junctional epithelium and the gingival fibers are referred to as the **dentogingival unit**. The dentogingival unit acts to provide structural support to the gingival tissue.

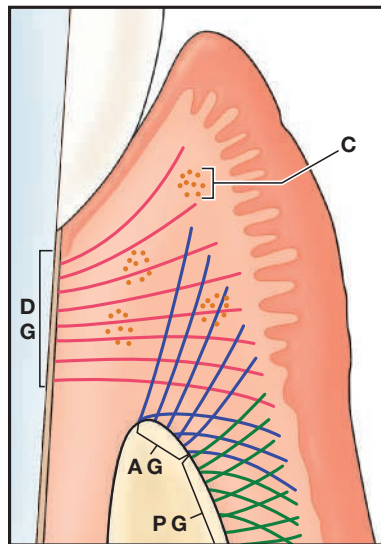
**B. Functions of the Gingival Fiber Bundles**

1. Brace the free gingiva firmly against the tooth and reinforce the attachment of the junctional epithelium to the tooth.
2. Provide the free gingiva with the rigidity needed to withstand the masticatory (chewing) forces.
3. Unite the free gingiva with the cementum of the root and alveolar bone.
4. Connect adjacent teeth to one another to maintain tooth positioning within the dental arch.

**C. Classification of Gingival Fiber Groups.** The supragingival fiber bundles are classified based on their orientation, sites of insertion, and the structures that they connect (Figs. 2-13 and 2-14).

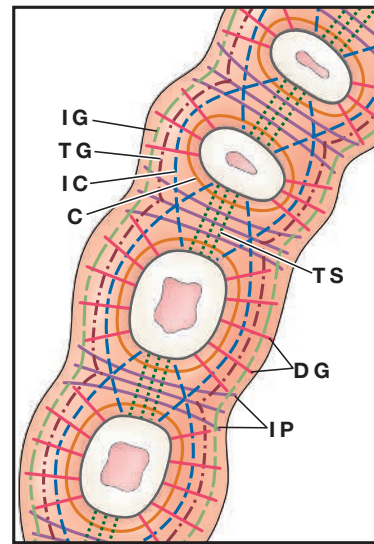
1. **Alveologingival fibers**—extend from the periosteum of the alveolar crest into the gingival connective tissue. These fiber bundles attach the gingiva to the bone. (The **periosteum** is a dense membrane composed of fibrous connective tissue that closely wraps the outer surface of the alveolar bone.)

2. **Circular fibers**—encircle the tooth in a ring-like manner coronal to the alveolar crest and are not attached to the cementum of the tooth.
3. **Dentogingival fibers**—embedded in the cementum near the CEJ and fan out into the gingival connective tissue. These fibers act to attach the gingiva to the teeth.
4. **Periosteogingival fibers**—extend laterally from the periosteum of the alveolar bone. These fibers attach the gingiva to the bone.
5. **Intergingival fibers**—extend in a mesiodistal direction along the entire dental arch and around the last molars in the arch. These fiber bundles link adjacent teeth into a dental arch unit.
6. **Intercircular fibers**—encircle several teeth. These fiber groups link adjacent teeth into a dental arch unit.
7. **Interpapillary fibers**—located in the papillae coronal to (above) the transeptal fiber bundles. These fiber groups connect the oral and vestibular interdental papillae of posterior teeth.
8. **Transgingival fibers**—extend from the cementum near the CEJ and run horizontally between adjacent teeth. These fiber bundles link adjacent teeth into a dental arch unit.
9. **Transeptal fibers**—pass from the cementum of one tooth, over the crest of alveolar bone, to the cementum of the adjacent tooth. These fiber bundles connect adjacent teeth to one another and secure alignment of teeth in the arch.



**Figure 2-13.** Supragingival Fiber Groups.

- C—circular
- AG—alveologingival
- DG—dentogingival
- PG—periosteogingival

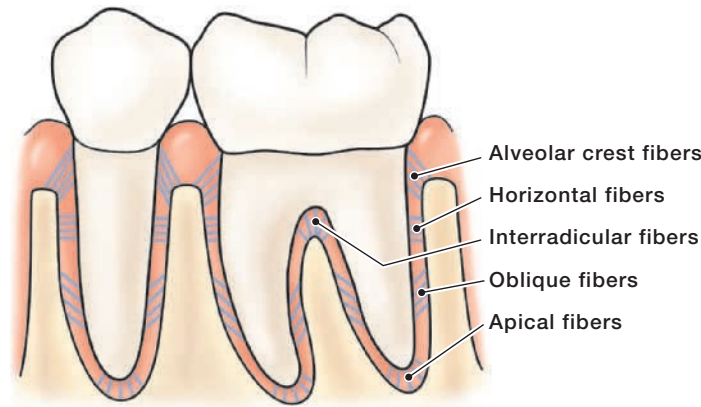


**Figure 2-14.** Supragingival Fiber Groups of the Mandibular Arch (Occlusal View, Looking Down on the Mandibular Arch).

- C—circular
- IG—intergingival
- IC—intercircular
- IP—interpapillary
- DG—dentogingival
- TG—transgingival
- TS—transeptal

#### 4. The Periodontal Ligament Fibers of the Gingival Connective Tissue

**A. Definition.** The **periodontal ligament (PDL)** is a thin sheet of fibrous connective tissue that surrounds the roots of the teeth and joins the root cementum with the socket wall. The thickness of the PDL space ranges from 0.05 to 0.25 mm depending on the age of the patient and the function of the tooth.<sup>17,18</sup>



**Figure 2-15. Principal Fiber Groups of the Periodontal Ligament.** The fibers of the PDL are classified as the alveolar crest, horizontal, interradicular, oblique, and apical.

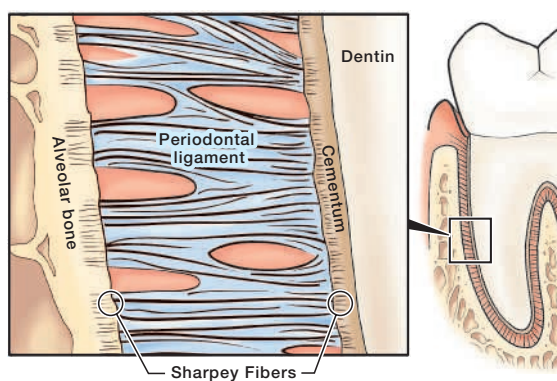
**B. Components of the Periodontal Ligament.** The periodontal ligament consists of connective tissue fibers, cells, and extracellular matrix.

1. Cells. The cells of the PDL are mainly fibroblasts with some cementoblasts and osteoblasts.
2. Extracellular Matrix.
  - a. The extracellular matrix of the PDL is similar to the extracellular matrix of other connective tissue. This rich gel-like substance contains specialized connective fibers.
  - b. Fiber Bundles. The **fiber bundles of the PDL** are a specialized connective tissue that surrounds the root of the tooth and connects it to the alveolar bone. These fibers are the largest component of the PDL.
    - 1) The rope-like collagen fiber bundles of the PDL stretch across the space between the cementum and the alveolar bone of the tooth socket (Fig. 2-15).
    - 2) The collagen fiber bundles are anchored on one side in the cementum covering the tooth root; on the other side, they are embedded in the bone of the tooth socket.
  - c. Blood Vessels and Nerve Supply. The PDL has a rich supply of nerves and blood vessels.

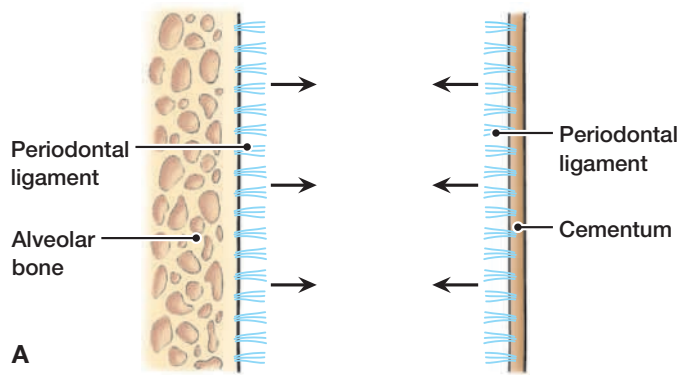
#### C. Functions of the Periodontal Ligament

1. Supportive function—the major function of the PDL is to anchor the tooth to its bony socket and to separate the tooth from the socket wall, so that the root does not traumatize the bone during mastication.
2. Sensory function—the PDL is supplied with nerve fibers that transmit tactile pressure (such as a tap with dental instrument against tooth) and pain sensations.

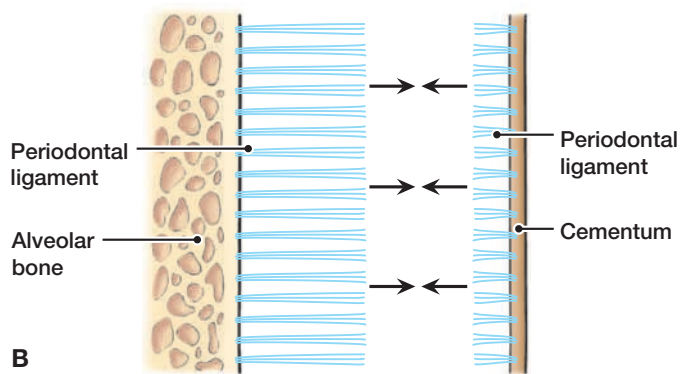
3. Nutritive function—the PDL is supplied with blood vessels that provide nutrients to the cementum and bone.
  4. Formative function—the PDL contains cementoblasts (“cementum builders”) that produce cementum throughout the life of the tooth, while the osteoblasts (“bone builders”) maintain the bone of the tooth socket.
  5. Resorptive function—in response to severe pressure, cells of the PDL (osteoclasts) can induce rapid bone resorption and, sometimes, resorption of cementum.
- D. Principal Fiber Groups of the PDL.** The tooth is joined to the bone by bundles of collagen fibers that can be divided into the five groups based on their location and orientation (Fig. 2-15).
1. **Alveolar crest fiber group**—extend from the cervical cementum, running downward in a diagonal direction, to the alveolar crest. This fiber group resists horizontal movements of the tooth and prevents tooth extrusion.
  2. **Horizontal fiber group**—located apical to the alveolar crest fibers. They extend from the cementum to the bone at right angles to the long axis of the root. This fiber group resists horizontal pressure against the crown of the tooth.
  3. **Oblique fiber group**—located apical to the horizontal group. They extend from the cementum to the bone, running in a diagonal direction. This fiber group resists vertical pressures that threaten to drive the root into its socket.
  4. **Apical fiber group**—extend from the apex of the tooth to the bone. This fiber group secures the tooth in its socket and resists forces that might lift the tooth out of the socket.
  5. **Interradicular fiber group** (present only in the furcation region of multirooted teeth)—extend from the cementum in the furcation area of the tooth to the interradicular septum of the alveolar bone. These fiber groups help to stabilize the tooth in its socket.
- E. Sharpey Fibers of the Periodontal Ligament**
1. The ends of the PDL fibers that are embedded in the cementum and alveolar bone are known as **Sharpey fibers** (Figs. 2-16 and 2-17).
  2. The attachment of the fiber bundles occurs when the cementum and bone are forming. As cementum forms, the tissue calcifies around the ends of the periodontal fibers (Sharpey fibers) surrounding them with cementum. The same process occurs during bone formation. As the bony wall of the tooth socket calcifies, it surrounds the ends of the periodontal fibers with bone. The ends of the fiber bundles become trapped in the bone that forms around them.



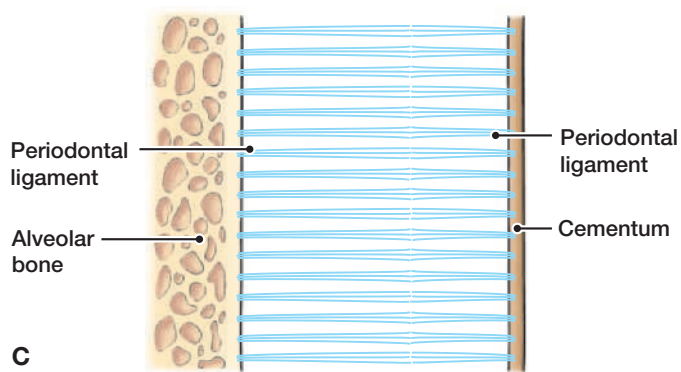
**Figure 2-16. Sharpey Fibers.** The ends of the periodontal ligament fibers that are embedded in the alveolar bone and the cementum are known as Sharpey fibers.



**A.** Fine collagen fibers arise from the root cementum. Similarly, collagen fibers arise from the alveolar bone proper.



**B.** The fibers grow into the mid-portion of periodontal ligament space.



**C.** The fibers from the root cementum fuse with fibers from the alveolar bone proper.

**Figure 2-17. Development of the Periodontal Ligament Fibers.** Figures **A**, **B**, and **C** depict the stages in the development of the periodontal ligament between the alveolar bone and the cementum of the tooth root.

## Section 3

# Histology of Root Cementum and Alveolar Bone

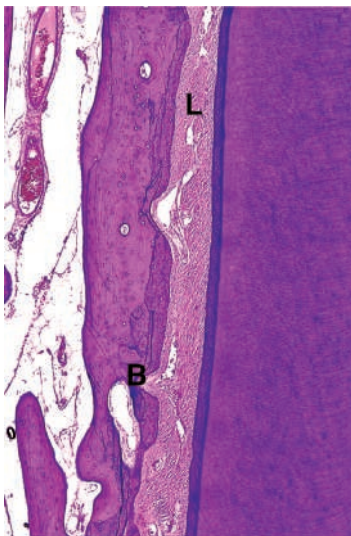
Section 3 reviews the microscopic anatomy of the cementum and alveolar bone. Knowledge of the microscopic anatomy of these structures is a prerequisite to understanding the function of these structures in health and the alterations in disease.

### MICROSCOPIC ANATOMY OF CEMENTUM

1. **Definition.** **Cementum** is a mineralized tissue that covers the roots of the teeth and serves to attach the tooth to alveolar bone via collagen fibers of the periodontal ligament (Fig. 2-18). Anatomically, cementum is part of the tooth, however, functionally it part of the periodontium.

#### A. Functions of Cementum

1. Its prime function is to attach the periodontal fibers to the root of the tooth.
2. Cementum maintains the integrity of the root, helps to maintain the tooth in its functional position in the mouth, and is involved in tooth repair and regeneration.
  - a. It seals and covers the open dentinal tubules and acts to protect the underlying dentin.
  - b. Cementum is slowly formed throughout life.
    1. Constant cementum formation allows for continual reattachment of the periodontal ligament fibers.
    2. Cementum continues to grow in thickness throughout life to compensate for attrition of teeth at their occlusal or incisal surfaces.<sup>19</sup> Cementum is formed at the apical areas of the roots to compensate for loss of tooth tissues due to attrition and maintains the length of the root.
3. Cementum is a key component of periodontal tissues, and its preservation is of paramount importance for the quality of healing at completion of periodontal treatment. Periodontal reattachment or new attachment as an end result of therapy strongly relies on the presence of cementum after root instrumentation.<sup>20</sup>
4. Cementum may influence the activities of various types of periodontal cells. It is believed that molecules stored in the cementum matrix may induce periodontal ligament regeneration when needed.<sup>20</sup>



**Figure 2-18. Cementum and Tooth Supporting Structures.**

- A thin layer of cementum (appearing as a **blue band**) covers the dentin of the root.
- The periodontal ligament (**L**) holds the tooth in the bony socket of the alveolar bone (**B**).

(Used with permission from Mills SE. *Histology for Pathologists*. 3rd ed. Philadelphia, PA: Lippincott Williams & Wilkins; 2006, Figure 15–39, p. 423.)

**B. Components of Mature Cementum.** As in bone and dentin, the major organic component of cementum is collagen. Cementum contains collagen fibers embedded in an organic matrix.<sup>21</sup>

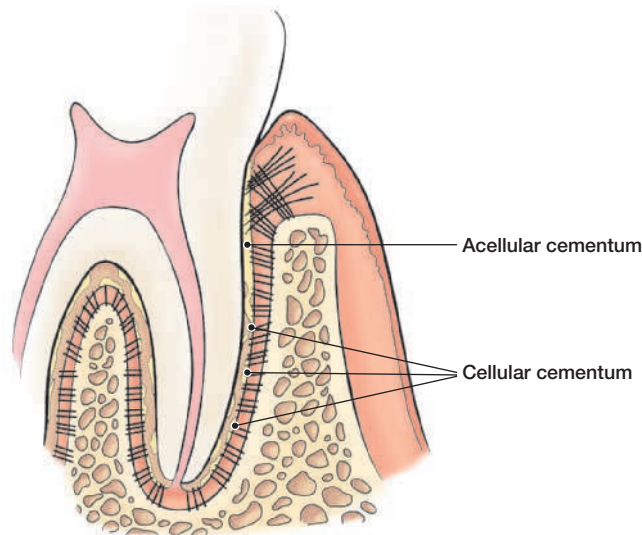
### 1. Organic Portion

- a. The organic matrix of cementum is composed of a framework of densely packed collagen fibers held together by the gel-like extracellular ground substance. These fibers are oriented more or less parallel to the long axis of the tooth.
- b. In addition to collagens, groups of proteins are present in cementum.
  1. Recent research suggests that these “**cementum proteins**” may have an important role in regulating the mineralization process associated with cementum formation.<sup>22</sup>
  2. There is still a great deal to learn about these cementum proteins. *From the current status of knowledge, it appears that cementum proteins may play an important role in future therapies to achieve regeneration of the periodontal structures.*<sup>22</sup>
2. **Mineralized Portion.** The mineralized portion of cementum is made up of hydroxyapatite crystals (calcium and phosphate).
3. **Vessels and Innervation.** Cementum contains no blood vessels or nerves. (Hypersensitivity of the root surface occurs when the cementum is removed exposing the dentin. It is the dentin that is sensitive to brushing, the touch of a dental instrument, or sudden temperature changes in the mouth (such as drinking hot coffee while eating ice cream.)
4. **Biologic Components.** From a biological perspective, the periodontium has been shown to contain biologically active mediators<sup>21,23–26</sup> and these molecules are elevated in alveolar bone and cementum.<sup>26–29</sup> It is believed that growth factor molecules are produced during cementum formation and then stored in the cementum matrix to induce periodontal ligament regeneration when needed.

**C. Conservation of Cementum During Periodontal Instrumentation.** Subgingival instrumentation during periodontal therapy results in the removal of root cementum, which can eventually lead to exposure of underlying dentin, pulp injury, and dentin hypersensitivity.<sup>30</sup>

1. **Historical Perspective.** Previously it was accepted that bacterial products penetrate the cementum of periodontally diseased root surfaces. This concept resulted in the intentional, aggressive removal of all or most cementum during periodontal instrumentation of root surfaces.<sup>31,32</sup> Overzealous instrumentation can result in removal of all cementum that may result in exposure of underlying dentin, tooth sensitivity, or even external root resorption. More specifically, in the past, the goal of periodontal therapy was to obtain a treated root surface with smooth and hard surface characteristics that was free of endotoxins.<sup>31,33</sup>
2. **Current Research**
  - a. More recent studies show that bacterial products are not located within cementum<sup>34,35</sup> and removal of cementum is not necessary for a successful periodontal treatment.<sup>36</sup>
  - b. The preservation of cementum on the root surface is further supported by Saygin et al. who report that cementum is necessary for new attachment and as a source of growth factors.<sup>21,37</sup>

- c. Grzesik and Narayanan suggested that cementum plays an important regulatory role in periodontal regeneration.<sup>38</sup> From these studies, it can be concluded that nonaggressive removal of cementum is necessary for optimal periodontal health as well as for periodontal regeneration.
2. **Types of Cementum.** Functional, morphological, and histological differences appear to exist along the length of the root.<sup>1,21,39</sup> Cementum is classified as follows: intermediate, acellular, and cellular cementum.
- A. Intermediate Cementum.** Cementum located in the CEJ.
- B. Acellular (Primary) Cementum.** Acellular cementum is primarily responsible for attaching the tooth to the alveolar bone (Fig. 2-19).
1. Contains no living cells within its mineralized tissue (no cementocytes)
  2. First cementum to be formed and covers approximately the cervical third or half of the root
  3. No new acellular cementum is produced after the tooth reaches the occlusal plane
  4. Thickness ranges from 30 to 230 microns
  5. Sharpey fibers make up most of the structure of acellular cementum
- C. Cellular (Secondary) Cementum.** Cellular cementum is distinguished by the presence of living cells in its structure.
1. Contains cementocytes and fibroblasts within its mineralized tissue
  2. Present in the apical and interradicular portions of the root
  3. Formed after the tooth reaches the occlusal plane and is less calcified than acellular cementum
  4. Deposited in intervals throughout the life of the tooth (thickness increases with age, where its increased thickness compensates for tooth attrition)
  5. Thickness ranges from 150 to 200 microns
  6. Sharpey fibers make up a smaller portion of cellular cementum



**Figure 2-19. Types of Cementum.** Acellular cementum covers approximately the cervical third or half of the root. New acellular cementum normally is not produced after the tooth has reached its occlusal plane. Cellular cementum covers the apical half of the root. It is continuously deposited throughout the life of the tooth after it has reached its occlusal plane and increases in thickness with age.

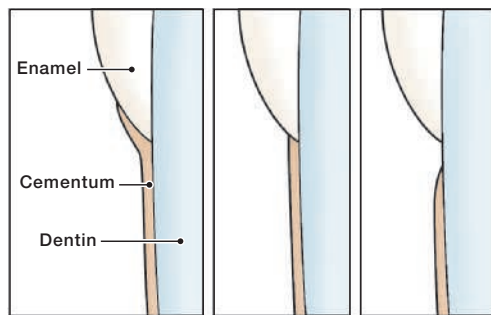
3. **Relationship of Cementum to Enamel at the CEJ.** The cementum covering the root may have any one of three relationships with the enamel of the tooth crown (Fig. 2-20).

**A. Three Possible Arrangements of Enamel and Cementum**

1. **Overlap**—the cementum overlaps the enamel for a short distance.
2. **Meet**—the cementum meets the enamel.
3. **Gap**—there is a small gap between the cementum and enamel (exposing the dentin in this area). The patient may experience discomfort (dentinal sensitivity) during instrumentation. The use of local anesthesia may be helpful during instrumentation, and desensitization of sensitive areas should be performed following instrumentation.

**B.** These three relationships commonly are abbreviated as **OMG (overlap, meet, gap)**.

**C.** *In any one tooth, all three arrangements of the junction between the cementum and enamel may be present.*<sup>19,21</sup>



**Figure 2-20. Three Patterns for the Arrangement of Cementum to Enamel at the Cementoenamel Junction.**

The cementum may (1) overlap the enamel, (2) meet the enamel, or (3) not meet, leaving a gap between the cementum and enamel.

## MICROSCOPIC ANATOMY OF ALVEOLAR BONE

1. **Definition.** The **alveolar process**—or alveolar bone—is the part of the maxilla and mandible that forms and supports the sockets of the teeth (Figs. 2-21 and 2-22).

2. **Function of Alveolar Bone in the Periodontium**

**A. Protects Roots of Teeth.** The alveolar bone forms the bony sockets that provide support and protection for the roots of the teeth.

**B. Changes in Response to Mechanical Forces and Inflammation.** Alveolar bone constantly undergoes periods of bone formation and resorption (loss) in response to mechanical forces on the tooth and inflammation of the periodontium. This process of bone formation and resorption is known as **bone remodeling**.

3. **Characteristics of Alveolar Bone**

**A. Components.** Alveolar bone is mineralized connective tissue made by cells called osteoblasts (“bone builders”).<sup>21</sup>

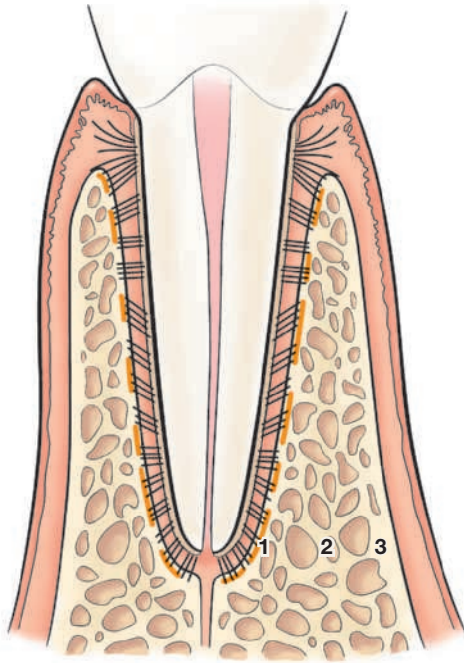
1. **Major Cell Types**

- a. **Osteoblasts**—bone-formers—cells that produce the bone matrix consisting of collagen fibers and other protein fibers.
- b. **Osteoclasts**—bone consumers—cells that remove the mineral materials and organic matrix of alveolar bone.

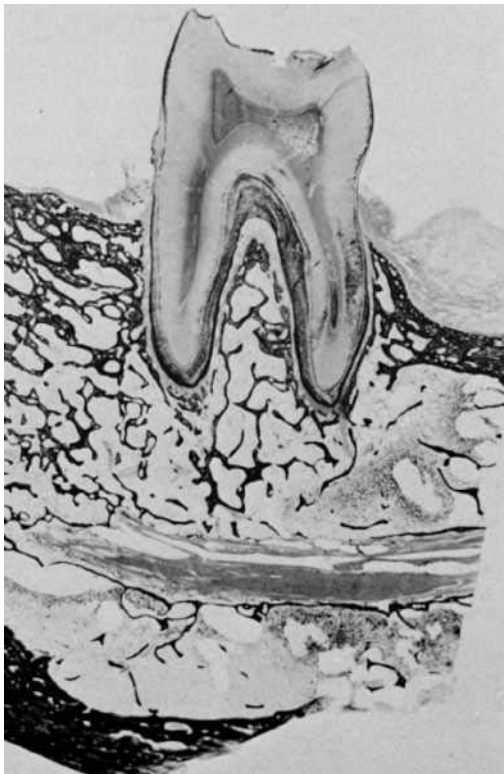2. **Extracellular Matrix**

- a. Collagen fibers and gel-like substance forms the major component of the alveolar bone

- b. The bone matrix is rigid because it undergoes mineralization by the deposition of minerals such as calcium and phosphate, which are subsequently transformed into hydroxyapatite.
- B. Vessels and Innervation.** The alveolar bone has blood vessels and nerve innervation.



**Figure 2-21. Anatomy of Alveolar Bone.** (1), Alveolar bone proper; (2), trabecular bone; and (3), cortical (compact) bone.



**Figure 2-22. Histology of Alveolar Bone.** A histologic section through a mandibular first molar and its alveolar process. (Used by permission from Melfi RC, Alley KE. *Permar's Oral Embryology and Microscopic Anatomy*. 10th ed. Philadelphia, PA: Lippincott Williams & Wilkins; 2000:215, Figure 9–20.)

## Chapter Summary Statement

---

Knowledge of the microscopic anatomy of the periodontium is fundamental in understanding the (1) function of the periodontium in health and (2) changes that occur during the periodontal disease process. The junctional epithelium plays an important role in the health of the periodontium by attaching the gingival epithelium to the tooth via hemidesmosomes and an internal basal lamina. In health, the periodontal ligament, cementum, and alveolar bone act as a functional unit to support and maintain the teeth in the oral cavity.

### Section 4

## Focus on Patients

---

### Clinical Patient Care

#### CASE 1

A clinician penetrates the oral mucosa with a needle before injecting a local anesthetic. The needle tip stops in the loose connective tissue underlying the surface structures. Name the layers of epithelium that have been penetrated by the needle.

#### CASE 2

A clinician finds it necessary to use a unique type of injection to achieve total anesthesia of a tooth being treated. The injection involves sliding a small-diameter needle into the PDL space to a point halfway down the tooth root. Name the PDL fibers most likely encountered by the needle tip during insertion.

#### CASE 3

Recession of the gingival margin exposes a portion of tooth root on a maxillary canine tooth. Microscopic examination of the cementum in the area of the crown margin on the canine will reveal what possible relationships between the level of cementum and the level of the tooth crown?

## Evidence in Action: Clinical Relevance

### Conservation of Cementum

Cementum is a key component of periodontal tissues, and its preservation is of paramount importance for the quality of healing at the completion of periodontal treatment. Conservation of cementum is ideal since loss of cementum is accompanied by exposure of the dentinal tubules and by a loss of attachment of PDL fibers to the root surface. Periodontal reattachment or new attachment as an end-result of therapy strongly relies on the presence of cementum after root instrumentation.

Research in the past 20 years has greatly advanced understanding of the cellular and molecular events involved in the developing periodontium. As understanding of the structure, function, and composition of cementum increases, so does the potential for new therapies for periodontal regeneration using molecules formed by these tissues.

Improper or aggressive periodontal instrumentation may reduce the thickness or eventually remove all the cementum over the root surface leading to a loss of growth factor reservoirs in the cementum. For this reason, it is strongly suggested that the root surface instrumentation should aim not only at thorough removal of calculus deposits but also at preserving root substance to improve healing following periodontal therapy.

### References

1. Cho MI, Garant PR. Development and general structure of the periodontium. *Periodontol 2000*. 2000;24:9–27.
2. Bartold PM, Walsh LJ, Narayanan AS. Molecular and cell biology of the gingiva. *Periodontol 2000*. 2000;24:28–55.
3. Weinmann JP, Meyer J. Types of keratinization in the human gingiva. *J Invest Dermatol*. 1959;32(2, Part 1):87–94.
4. Listgarten MA. Electron microscopic study of the gingivo-dental junction of man. *Am J Anat*. 1966;119(1):147–77.
5. Dale BA. Periodontal epithelium: a newly recognized role in health and disease. *Periodontol 2000*. 2002;30:70–78.
6. Listgarten MA. The ultrastructure of human gingival epithelium. *Am J Anat*. 1964;114:49–69.
7. Schroeder HE. Ultrastructure of the junctional epithelium of the human gingiva. *Helv Odontol Acta*. 1969;13(2):65–83.
8. Schroeder HE, Listgarten MA. The gingival tissues: the architecture of periodontal protection. *Periodontol 2000*. 1997;13:91–120.
9. Thilander H, Bloom GD. Cell contacts in oral epithelia. *J Periodontol Res*. 1968;3(2):96–110.
10. Pollanen MT, Salonen JI, Uitto VJ. Structure and function of the tooth-epithelial interface in health and disease. *Periodontol 2000*. 2003;31:12–31.
11. Sabag N, Saglie R, Mery C. Ultrastructure of the normal human epithelial attachment to the cementum root surface. *J Periodontol*. 1981;52(2):94–95.
12. Schroeder HE, Listgarten MA. The junctional epithelium: from strength to defense. *J Dent Res*. 2003;82(3):158–161.
13. Schroeder HE, Theilade J. Electron microscopy of normal human gingival epithelium. *J Periodontol Res*. 1966;1(2):95–119.
14. Bartold PM. Connective tissues of the periodontium—preface. *Periodontol 2000*. 2000;24:7–8.
15. Bartold PM. Connective tissues of the periodontium. Research and clinical implications. *Aust Dent J*. 1991;36(4):255–268.
16. Wang Y, Wang Q, Arora PD, Rajshankar D, McCulloch CA. Cell adhesion proteins: roles in periodontal physiology and discovery by proteomics. *Periodontol 2000*. 2013;63(1):48–58.
17. Beertsen W, McCulloch CA, Sodek J. The periodontal ligament: a unique, multifunctional connective tissue. *Periodontol 2000*. 1997;13:20–40.
18. Ho SP, Marshall SJ, Ryder MI, Marshall GW. The tooth attachment mechanism defined by structure, chemical composition and mechanical properties of collagen fibers in the periodontium. *Biomaterials*. 2007;28(35):5238–5245.
19. Bosshardt DD, Selvig KA. Dental cementum: the dynamic tissue covering of the root. *Periodontol 2000*. 1997;13:41–75.
20. Bozbay E, Dominici F, Gokbuget AY, et al. Preservation of root cementum: a comparative evaluation of power-driven versus hand instruments. *Int J Dent Hyg*. 2018;16:202–209.
21. Saygin NE, Giannobile WV, Somerman MJ. Molecular and cell biology of cementum. *Periodontol 2000*. 2000;24:73–98.
22. Arzate H, Zeichner-David M, Mercado-Celis G. Cementum proteins: role in cementogenesis, biomineralization, periodontium formation and regeneration. *Periodontol 2000*. 2015;67(1):211–233.
23. Bartold PM, McCulloch CA, Narayanan AS, Pitaru S. Tissue engineering: a new paradigm for periodontal regeneration based on molecular and cell biology. *Periodontol 2000*. 2000;24:253–269.
24. Cochran DL, Wozney JM. Biological mediators for periodontal regeneration. *Periodontol 2000*. 1999;19:40–58.
25. MacNeil RL, Somerman MJ. Development and regeneration of the periodontium: parallels and contrasts. *Periodontol 2000*. 1999;19:8–20.

26. Nishimura K, Hayashi M, Matsuda K, Shigeyama Y, Yamasaki A, Yamaoka A. The chemoattractive potency of periodontal ligament, cementum and dentin for human gingival fibroblasts. *J Periodontal Res.* 1989;24(2):146–148.
27. Miki Y, Narayanan AS, Page RC. Mitogenic activity of cementum components to gingival fibroblasts. *J Dent Res.* 1987;66(8):1399–1403.
28. Nakae H, Narayanan AS, Raines E, Page RC. Isolation and partial characterization of mitogenic factors from cementum. *Biochemistry.* 1991;30(29):7047–7052.
29. Somerman MJ, Archer SY, Hassell TM, Shteyer A, Foster RA. Enhancement by extracts of mineralized tissues of protein production by human gingival fibroblasts in vitro. *Arch Oral Biol.* 1987;32(12):879–883.
30. Fischer C, Wennberg A, Fischer RG, Attstrom R. Clinical evaluation of pulp and dentine sensitivity after supragingival and subgingival scaling. *Endod Dent Traumatol.* 1991;7(6):259–265.
31. Jones WA, O’Leary TJ. The effectiveness of in vivo root planing in removing bacterial endotoxin from the roots of periodontally involved teeth. *J Periodontol.* 1978;49(7):337–342.
32. O’Leary TJ. The impact of research on scaling and root planing. *J Periodontol.* 1986;57(2):69–75.
33. Chace R. Subgingival curettage in periodontal therapy. *J Periodontol.* 1974;45(2):107–109.
34. Moore J, Wilson M, Kieser JB. The distribution of bacterial lipopolysaccharide (endotoxin) in relation to periodontally involved root surfaces. *J Clin Periodontol.* 1986;13(8):748–751.
35. Nakib NM, Bissada NE, Simmelink JW, Goldstine SN. Endotoxin penetration into root cementum of periodontally healthy and diseased human teeth. *J Periodontol.* 1982;53(6):368–378.
36. Nyman S, Westfelt E, Sarhed G, Karring T. Role of “diseased” root cementum in healing following treatment of periodontal disease. A clinical study. *J Clin Periodontol.* 1988;15(7):464–468.
37. Narayanan AS, Bartold PM. Biochemistry of periodontal connective tissues and their regeneration: a current perspective. *Connect Tissue Res.* 1996;34(3):191–201.
38. Grzesik WJ, Narayanan AS. Cementum and periodontal wound healing and regeneration. *Crit Rev Oral Biol Med.* 2002;13(6):474–484.
39. Zeichner-David M. Regeneration of periodontal tissues: cementogenesis revisited. *Periodontol 2000.* 2006;41:196–217.



## STUDENT ANCILLARY RESOURCES

A wide variety of resources to enhance your learning is available online:

- Audio Glossary
- Book Pages
- Chapter Review Questions and Answers